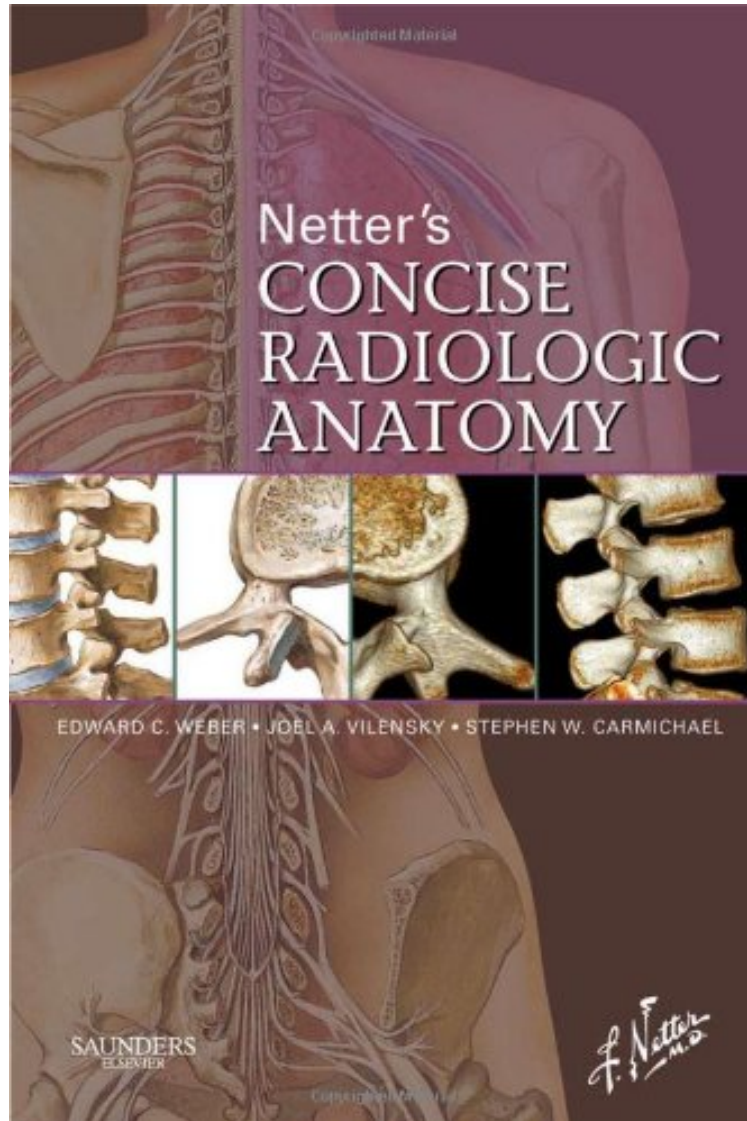


[Mobile ebook] Netter's Concise Radiologic Anatomy, 1e (Netter Basic Science)

## Netter's Concise Radiologic Anatomy, 1e (Netter Basic Science)

*Edward C. Weber DO, Joel A. Vilensky PhD, Stephen W. Carmichael PhD DSc, Kenneth S. Lee MD  
DOC | \*audiobook | ebooks | Download PDF | ePub*



[Download](#)

[Read Online](#)

#1470873 in Books Saunders 2008-07-23 Ingredients: Example Ingredients Original language: English PDF # 1.80 x 6.00 x 8.80l, 1.60 #File Name: 141605619X512 pages | File size: 76.Mb

**Edward C. Weber DO, Joel A. Vilensky PhD, Stephen W. Carmichael PhD DSc, Kenneth S. Lee MD : Netter's Concise Radiologic Anatomy, 1e (Netter Basic Science)** before purchasing it in order to gage whether or not it would be worth my time, and all praised Netter's Concise Radiologic Anatomy, 1e (Netter Basic Science):

1 of 1 people found the following review helpful. If you like picture books, this is for you. By Tim Edwards They should call this "Netter's Concise and Incomplete Radiologic Anatomy". It is really lacking. Here is an example: If you want to see the brachial plexus - they have a page with it (one page), and on that page they marked the lateral cord (of

course), the medial cord (naturally), and the... That's it. Well, they also marked the upper trunk. So there you have it - the brachial plexus ladies and gentlemen. How about the foramina of the skull - they marked most of them, but the stylomastoid foramen? Nope. It's staring you right in the face and nope. How about the foramen magnum - arguably the most important one. No. They don't even name it. I'm not sure the usefulness of showing a 3D volumetric CT representation that is identical to the netter drawing either. You just showed us the illustration. Now you are essentially showing us another illustration. But then each page has a clinical pearl. There are 430 or so in this book. They are a sentence describing one thing about a pathology related to the anatomy. If these 430 were all you needed, you'd be living in 500BC. 3 of 3 people found the following review helpful. Not a true radiologic atlas. By Neospinoza The radiographic images add very little to the book because the vast majority are reconstructions never seen in practice or are odd angles not usually imaged. The book would have been much better by correlating standard radiographic CT scans and MRI's with the Netter drawings. As presented here, the radiographic images are little more than gee-whiz reproductions of the Netter drawings, and as such, add very little. I don't understand the purpose of the book. 0 of 0 people found the following review helpful. Big savings than local book store. By Abaomair Dont waste your money by purchasing books from local or college book store. Make sure u get the right volum recommended from school and save big purchasing from .

Designed to make learning more interesting and clinically meaningful, this new resource matches radiologic images including advanced reconstruction to the exquisite artwork of master medical illustrator Frank H. Netter, MD. In contrast to all other anatomic/radiologic atlases available, Netter's Concise Radiologic Anatomy begins with the anatomy and matches radiologic images to the anatomic images that are indelibly etched in the minds of those who refer to Netter's Atlas of Human Anatomy on a daily basis. Concise text enables you to quickly and conveniently access the key anatomic and radiologic knowledge associated with the images. Organized and color-coded in the same manner as Netter's Atlas of Human Anatomy, it's a perfect companion guide to the Atlas and a perfect guide for understanding the clinical context of normal anatomy. Presents side-by-side radiology examples of normal anatomy and common variants with corresponding anatomy illustrations, demonstrating the clinical relevance of the anatomy and providing direct, at-a-glance comparisons between idealized anatomic illustrations and real-life medicine. Includes a brief background in basic radiology including reconstructions and a list of common abbreviations to provide a foundation of knowledge for the images presented. Follows the same organization and color-coded format of Netter's Atlas of Human Anatomy, for easy reference.

"Overall, I would recommend this book as a useful adjunct for the medical gross anatomy student, particularly those with an interest in radiology or surgery. While it does not attempt to replace the standard anatomic atlas, or supplant more definitive radiologic imaging references, the application of image reconstruction provides a novel way to transition from anatomic illustrations to the complexities of advancing radiologic image presentation." --Clinical Anatomy "The authors state that their intention is to "expose" any student of anatomy" to radiologic images and to show how "modern radiology portrays human anatomy." They definitely accomplished this task. However, the handbook (as the authors refer to this atlas) does require one to have priori knowledge about human gross anatomy. This atlas is a worthwhile addition to anyone's collection of anatomical reference books and would probably be most effectively used by students in their clerkships or residents when correlating radiologic images to the anatomy that they may have forgotten, but should remember!" --American Association of Anatomists "The Netter diagrams are superb. The quality of the matching radiological images is also quite superb. It fulfills its mission of correlating high quality radiological images with Netter anatomy drawings. It provides the reader with a modern high quality radiological atlas, which would be of interest to medical students, allied health professionals, surgical and radiology residents and indeed most hospital based practicing doctors." - M.J. Lee, Surgeon journal "We read with interest the audit article of Mohamed et al. They report 50 consecutive cases of intra-gastric balloon therapy (IBT) with complications in four cases. At our district general hospital, we have no experience of this technique, except the following. A 36-year-old woman presented six weeks after having IBT performed by a specialist in an eastern European city. She made an unremarkable recovery from the procedure and returned home to the UK." Netter's Concise Radiologic Anatomy December 2009